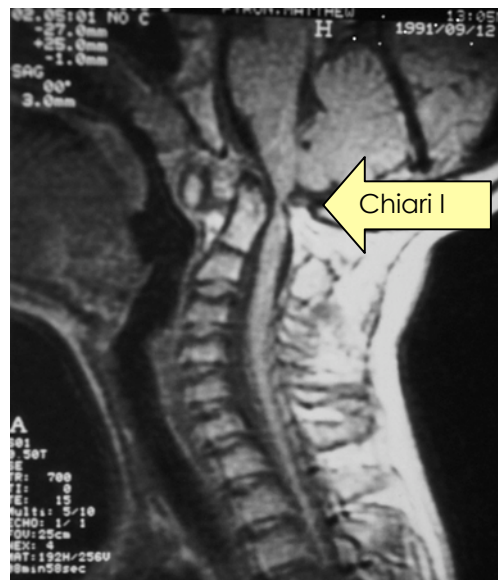


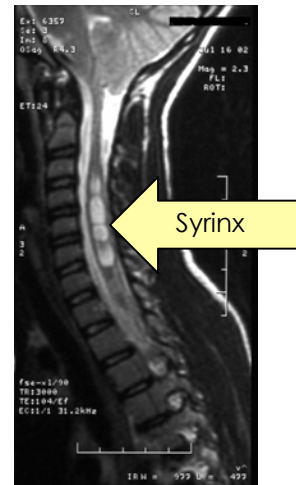
SPINAL DYSRAPHISM

A child who has back pain, neck pain, misshapen vertebrae, painful scoliosis, excessive hamstring tightness, unusually high arches or muscle weakness may need to be evaluated with an MRI of the spine. The MRI is a test used to determine whether the spinal cord is normal or has a type of **spinal dysraphism**. The significant forms of spinal dysraphism are birth defects of the spinal cord. These conditions are **Chiari I** malformation, **syringomyelia** (also called a **syrinx**), **tethered spinal cord**, and split cord (called **diastematomyelia**).

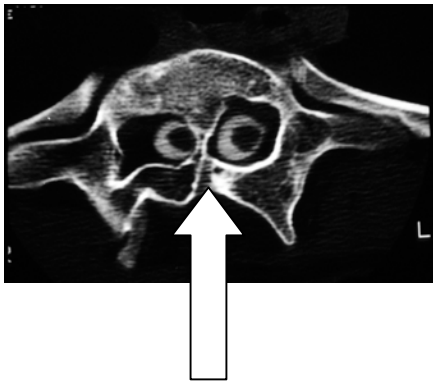
A **Chiari I** malformation is a narrowed opening at the base of the skull. Through this opening the spinal cord exits the skull and enters the spinal column. If this opening is narrow the area of the brain that connects to the spinal cord, called the cerebellar tonsils, may be pinched or squeezed. This narrowing may also affect the flow of the spinal fluid, which normally surrounds the brain and spinal cord.



A **syringomyelia** or **syrinx** is an abnormal build up of fluid within the spinal cord. This abnormal collection of fluid may put pressure on the nerves and pathways in the spinal cord.

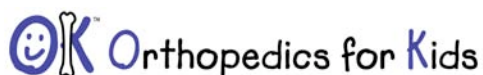

A **tethered cord** is a tight, thickened band at the bottom of the spinal cord that forms an abnormal attachment to the base of the spine. The band tugs on the spinal cord and the nerves that go to the legs.



Diastematomyelia means a "split cord". A patient with a Diastematomyelia has a band or bony spur that digs into the spinal cord or splits the spinal cord into two pieces.

The identification of these abnormalities may be significant in determining the care plan for your child. If a form of spinal dysraphism is identified, the care of your child may include the participation of a pediatric neurologist or neurosurgeon.



2660 10th Avenue South • POB 1 • Birmingham, AL 35205 • 205-933-8588

All of the content and images on this Brochure are protected by United States and International copyright law and may not be copied, scanned, reproduced, published or altered in any way without written permission.

© John T. Killian, MD 2009