

Scoliosis and Rett Syndrome

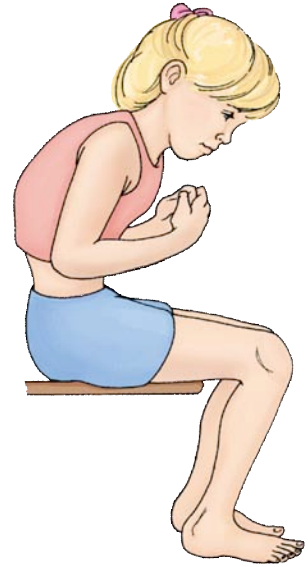The muscles of the spine function to keep the spine straight. The development of changes in the alignment of the spine in children with Rett syndrome is most likely caused by poor muscle control, poor coordination, or an asymmetrical muscle pull. This scoliosis is considered to be neuromuscular, or caused by the imbalance of the muscles of the spine. The development of scoliosis, a lateral bending and twisting of the spine, is less likely to develop in the Rett child who continues to ambulate.

During growth spurts, between ages eight to fourteen, the spine becomes longer. It is during this time that scoliosis usually begins to develop. The vertebrae not only bend sideways, but also rotate and begin to “stiffen” into place as the curve gets larger. Bracing may be a temporary aid for positioning the child in their wheelchair, but the brace has no effect in delaying or halting the progression of the curve.

As the curve increases, the pelvis may begin to tilt into the curve and cause the child to be seated on just one hip. The pelvis may begin to rub up against the rib cage causing irritation and pain. Breathing may become more difficult and stomach function may be affected as well. Sitting for any period of time may become more difficult secondary to pain. The child may have to be reclined in their chair, which makes interaction with peers and family members more difficult, if not impossible.

Once the curve begins to progress, treatment should be initiated. Exercise, bracing, and manipulations have no impact on the outcome of neuromuscular scoliosis. If scoliosis is allowed to progress naturally, there is no certainty that it will become so severe to prevent sitting, although it does occur in the majority of cases. One also needs to consider that some loss of respiratory and gastric function will occur as the curve increases to above 60 degrees.

Indications for treatment involve consideration of the child's remaining growth, as well as the severity and stiffness of the curve. It is best to perform surgery while the child is in good health; the curve is no more than 40-50 degrees and is still flexible. In most cases, the surgery is done as one procedure from behind. This is called a posterior spinal fusion. If the curve has been allowed to progress to more than 90 degrees and is now stiff, the surgery would be more complex and would involve going in on the front of the spine as well as from behind. This is called an anterior/posterior spinal fusion.



Clinical Guidelines for Management of Scoliosis in Rett Syndrome

Monitoring and intervention prior to diagnosis:

1. All children with a clinical diagnosis of RTT should undergo genetic testing as genotype may influence development and management of scoliosis
2. Because there is a high prevalence of scoliosis in Rett, families should be given information about this early in the child's clinical course
3. Physical assessment of spine should be conducted at time of diagnosis and every 6 months after diagnosis
4. Therapy should aim to:
 - Develop, maintain and promote walking for as long as possible
 - Optimize strength of the back extensors
 - Maintain flexibility of the spine
 - Implement postural management scheme that includes appropriate support for correct sitting posture and sleeping posture supports.

Monitoring after diagnosis of scoliosis

1. Referral to orthopedic surgeon when there is clinical concern regarding scoliosis
2. Physical examination of the spine every 6 months, but the frequency of assessment should be increased in the following situations:
 - Abnormal early development /never learning to walk
 - Low muscle tone
 - During growth spurts
 - Early age onset
 - Greater Cobb angle
 - Children with genotypes known to be at higher risk of more severe scoliosis
3. Physical assessment in Rett should include:
 - Sitting balance and symmetry of weight bearing in sitting
 - Level of walking ability and time spent walking
 - Total distance walked
4. Height and weight should be monitored at each visit

Imaging

1. Request an initial x-ray if there is evidence of a curve
2. Assess skeletal maturity by hand/wrist x-ray (bone age) or assessment of iliac growth (Risser)
3. X-ray every 6 months if Cobb angle is greater than 25 degrees before skeletal maturity and every 12 months after skeletal maturity until evidence of no further progression
4. Plain x-rays are sufficient to monitor curve progression. The following views should be obtained and should include shoulder to pelvis:
 - Standing upright AP and lateral spine for patients who can stand at initial visit
 - Sitting AP and lateral spine for patients who cannot stand
 - Supine AP and lateral spine for patients who cannot sit
5. AP films alone can be used in follow-up

Therapy and Conservative Management

1. Involve PT/OT as soon as scoliosis is diagnosed

2. PT should be used to maintain musculoskeletal well being. There is no evidence that PT will prevent progression of the scoliosis curve
3. Aim to prolong ambulation as long as possible. Aim to increase distance that child can walk and/or the length of time the child can stay on their feet
4. For those who cannot walk, use standing frames for at least 30 minutes each day
5. Aim to maintain range of motion of all joints
6. Symmetrical seating is valuable for the child's comfort and functioning
7. Assess, monitor and optimize Vitamin D levels. Improve dietary intake of calcium and time spent in daylight to promote bone health.
8. In severe scoliosis where surgery is not indicated, the management plan should include:
 - Provision of supported seating to optimize posture
 - Monitoring and treatment of pressure sores
 - A low threshold for antibiotic use during respiratory infections to minimize the effects of restrictive lung disease

Spinal bracing

1. There is no consensus that bracing is beneficial in reducing the progression of scoliosis but it may be used if seating and trunk activation cannot be achieved
2. If tolerated, bracing should be used in the skeletally immature child, to postpone surgery
3. The following potential complications of bracing must be considered: pressure sores, respiratory impairment, discomfort, skin irritation, exacerbation of gastro-esophageal reflux and the potential to decrease trunk strength, flexibility and physical activity.

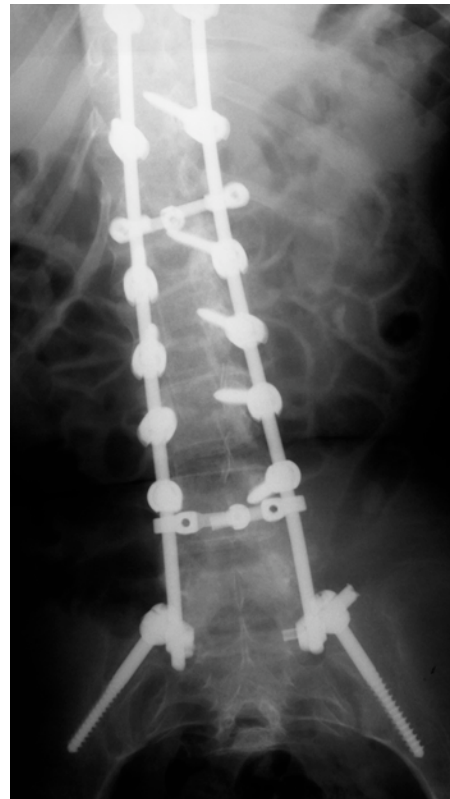
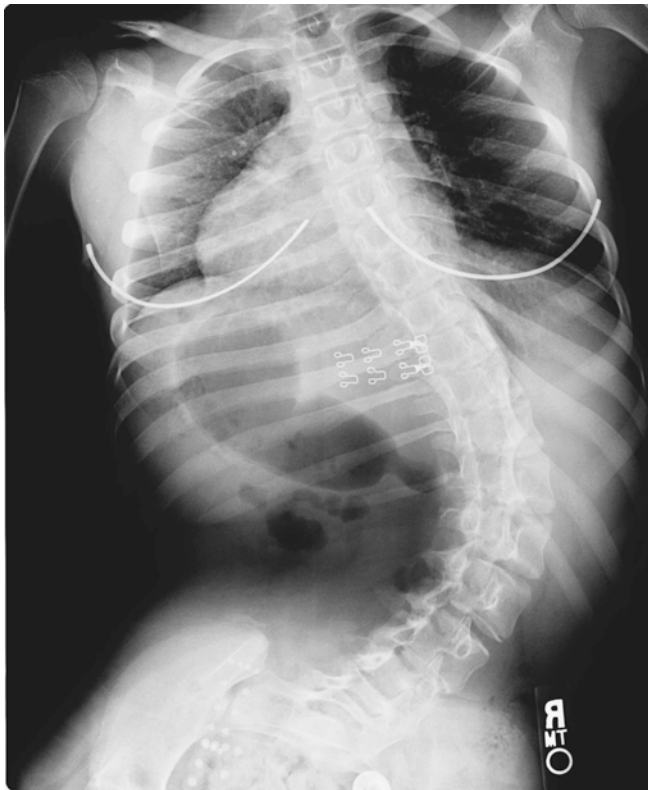
Pre-operative considerations

1. Surgery should be performed in a specialist center due to the high risk of anesthesia and post-surgical complications
2. Surgery should not be delayed until skeletal maturity has been achieved, however, caution should be used before performing surgery in children less than 10 years of age due to the following problems: decreased trunk height, pulmonary restriction, "crankshaft", and secondary curvatures
3. Surgery should be performed when the Cobb angle is approximately 40-50 degrees
4. Surgical objectives should include:
 - Achieving a spine that is balanced and fused
 - Restoration of the normal sagittal profile
 - Achieving level shoulders and hips
 - Improving the well-being and functioning of the child
5. There should be a period of hyperalimentation if weight is less than the 5th percentile
6. Markers of nutrition should be assessed: BMI, hemoglobin, electrolytes, albumin, and white cell count
7. Patients with Rett syndrome need special anesthetic consideration. They are highly sensitive to analgesia, sedatives, and volatile anesthetic agents.
8. In addition to pre-operative assessment used in all scoliosis surgery, the following must be considered before anaesthetizing a child with Rett syndrome:
 - Breathing patterns (hyperventilation, breath holding)
 - Pre-operative arterial blood gases/capillary gases

- Gastro-esophageal Reflux
- Autonomic disturbance
- Seizure history, management and medications
- Pre-operative ECG to identify possible prolonged QT syndrome

Surgical considerations

1. In the majority of cases it will be possible to use a posterior only spinal fusion. This is the definitive management of neuromuscular scoliosis in girls with Rett
2. If anteroposterior surgery must be used, a single stage approach is preferable in order to reduce anesthetic and surgical complications but a staged procedure may be appropriate in the presence of significant co-morbidities.
3. Fixation to the pelvis is indicated if pelvic obliquity exists in the non-ambulatory child.
4. If a reliable signal can be obtained, Motor Evoked Potentials and/or Somatosensory Evoked Potentials can be used to detect neurological injury during neuromuscular scoliosis surgery.



Post-operative considerations

1. Admit to ICU postoperatively
2. Care needs to be taken with regards to analgesia titration so that pain relief is adequate and sedation is minimized to ensure respiratory effort is not compromise. Post-operative analgesia must be closely monitored by a pediatric pain specialist team with 24 hour coverage or Intensive Care specialists.
3. Frequent and aggressive chest PT should be used. Non-invasive positive airway pressure support may be required post extubation.

4. A clear management plan should be constructed when the patient is transferred to the ward
5. Seek expert advice to optimize nutritional status
6. Consult parents or caregivers to help assess the child post-operatively.
7. Mobility post-op:
 - Log roll for bed mobility
 - Sitting on edge of bed day one post-op
 - Transfer to chair post-op day two
 - Walking (if possible) post-op day three
8. Post-operative reviews should be carried out at;
 - 6 weeks
 - Then every two-three months over the first year
 - Annually there after
9. The following should be used to assess surgical outcome: complications including bleeding, infection and duration of ICU stay; Cobb angle and achievement of fusion; respiratory status; sitting balance, function and quality of life.