

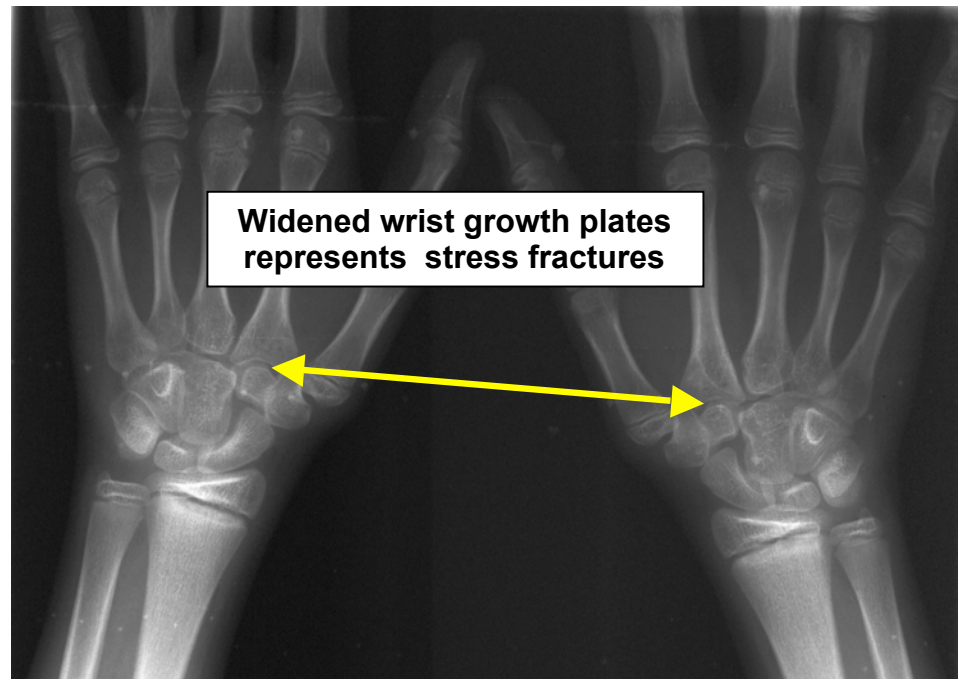
# STRESS FRACTURES

The incidence of stress fractures in children and adolescents is increased with year round sports involvement. Stress fractures are the result of repetitive injuries that interfere with the normal production of bone and bone remodeling. The bones that are most commonly affected by stress fractures include the proximal tibia, the femoral neck, the femoral shaft, the distal femoral metaphysis, the medial malleolus, the metatarsus and the pars interarticularis.

While the absolute incidence of stress fractures is not known, the risk factors have been clearly defined. These include individuals who have small muscle mass, combination of mild muscle weakness in one muscle group and muscle tightness in another muscle group, ligamentous laxity, and high risk activities such as back flips, handstands, weightlifting, and certain contact sports

It is important that a pediatric orthopedic surgeon evaluate the child because of the potential that the pain and discomfort is associated with an infection, juvenile rheumatoid arthritis, a benign tumor, or even a malignancy. X-rays may be helpful in the identification of a stress fracture.

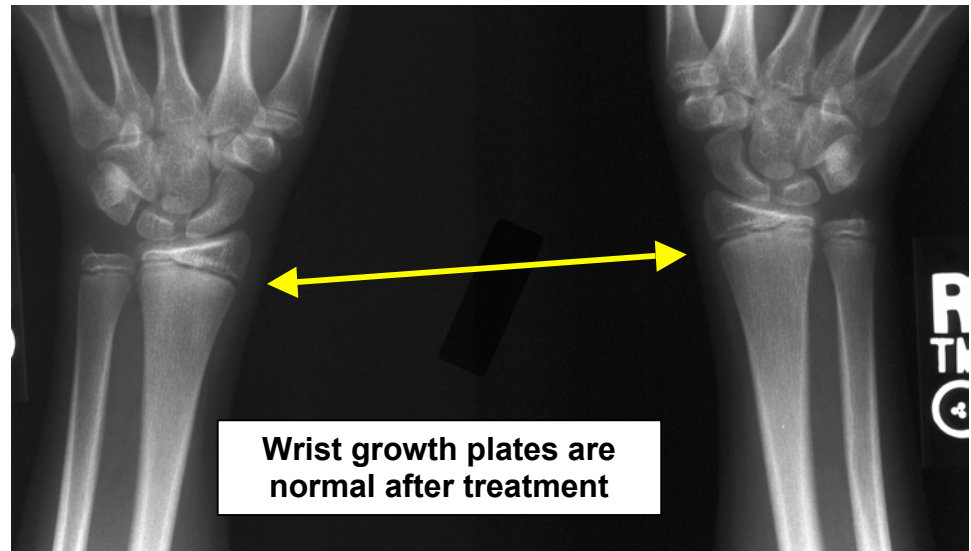
The x-rays will demonstrate new bone formation that is in the area where the bone has been damaged.



Bone scans may involve the injection of a technetium material that may also help diagnose stress fractures. The technetium is concentrated in areas of recent bone injury or abnormal bone turnover. However bone scans cannot differentiate between a stress fracture, infection, or tumor. MRIs have been more helpful in terms of differentiating stress fractures from infection and cancer and are more likely to be used in equivocal cases.



The management of a chronic stress fracture depends on the location, severity of the symptoms, and age of the patient. Most patients respond well to cessation of vigorous running activities or gymnastic-type events. Cast immobilization or splinting may be required, and resumption of normal activities does not occur until the x-rays and clinical exam are normal.



In rare individuals the stress fractures fail to heal. Operative treatment may be combined with bone grafting to that area and internal fixation of the damaged bone to try and promote healing.

Resuming a competitive sports activity is an issue that the parent and child will have to consider seriously after the stress fracture has healed. Obviously the child's inability to complete the training schedule due to fatigue and risk factors contributed to the stress fracture. Modification or elimination of particular maneuvers and attention to training methods may be required in order to allow the child to return to that sports activity again.



2660 10<sup>th</sup> Avenue South • POB 1 • Birmingham, AL 35205 • 205-933-8588

All of the content and images on this Brochure are protected by United States and International copyright law and may not be copied, scanned, reproduced, published or altered in any way without written permission.

© John T. Killian, MD 2009