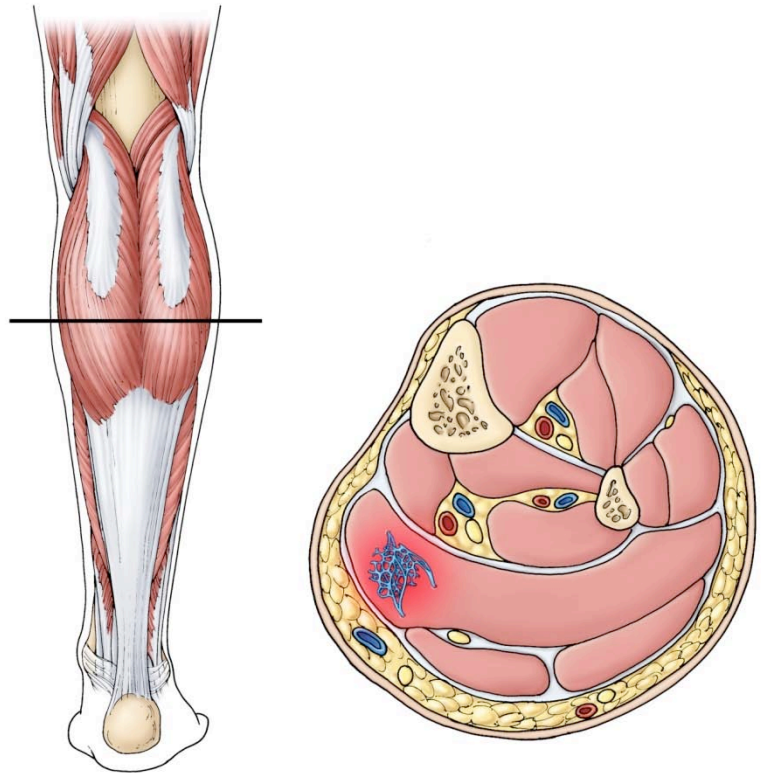


# HEMANGIOMAS OF MUSCLE AND BONE

Blood vessels are present in muscles and bone. Blood flows through these small tubes bringing nutrition to cells and removing waste products. The growth of blood vessels is under tight control of the body's internal regulation systems.

Abnormal growth or enlargement of blood vessels within the muscle or bone produces a "hemangioma". A hemangioma may occur at any age and does not usually cause symptoms. If symptoms do occur, pain and localized swelling in the affected muscle are most common. Hemangiomas in the bone may be characterized by persistent pain, especially at night.



Often, hemangiomas are detected on x-ray taken for some other reason. They appear as a polka dot pattern of calcium deposits in the muscle or as a washed out area in the bone.

Biopsy of a hemangioma may be recommended either because of sudden enlargement of the mass or increasing pain. The differential diagnosis includes two cancerous conditions called angiosarcomas and hemangioendotheliomas.

The options for treatment of benign hemangiomas in muscles include compression type stockings that attempt to limit the lesion from enlarging, or injecting the hemangioma with a caustic material to shrink the hemangioma. Complete surgical removal of a hemangioma in a muscle is

nearly impossible. Removing part of a hemangioma to decrease its size may be performed in rare circumstances. If the hemangioma is in the bone options for treatment include low dose radiation and injections that cause blockage of the blood vessels that lead to the hemangioma. Treatment of hemangioma of the bone is most commonly done when the spinal cord is affected.

In general, hemangiomas are benign conditions that are usually not present at birth but appear shortly afterward. The triggering mechanism for these has not been established. Fortunately, for most children, these benign lesions are simply observed and treatment is rarely necessary



2660 10<sup>th</sup> Avenue South • POB 1 • Birmingham, AL 35205 • 205-933-8588

All of the content and images on this Brochure are protected by United States and International copyright law and may not be copied, scanned, reproduced, published or altered in any way without written permission.

© John T. Killian, MD 2009