

Are my child's legs and feet normal??

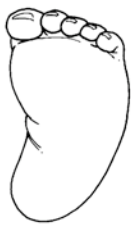In examining your child, the pediatric orthopaedic surgeon will assess several things

1. Are your child's sitting or standing balance and muscle tone good?
2. Is the appearance of the foot normal?
3. Is the foot aligned with the kneecap?
4. Are the hips limited from rotating back and forth?
5. Are the legs straight when standing?
6. If your child can walk, is it normal for the age?

One or more of these diagnoses may describe your child's condition:

Muscle Imbalance Problem

This is a term to describe an infant who is not sitting up by 10 months of age, has not begun to cruise the furniture at 18 months of age or demonstrates muscle weakness. A specific diagnosis may require additional testing or the input of other specialists.

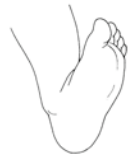

Metatarsus Adductus (MTA)

The front part of the foot is hooked inward and gives the foot a C-shaped appearance. Under 4 months of age, stretching of the tight muscle is needed to restore a straight appearance to the foot. From 4-12 months of age, stretching, splinting, and casting may be suggested.


Calcaneovalgus Foot

In the womb, the foot may be pressed up against the front of the shin bone. In some cases it may remain in that position after birth. Frequent massage and stretching of the foot usually results in a normal foot



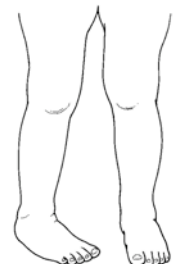
Flexible Flatfoot

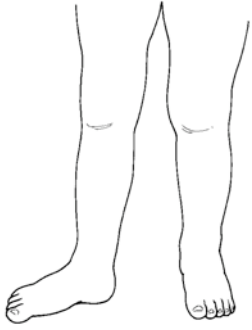The infant's foot may not appear to have a normal arch. If the foot is flexible, then no treatment is needed. From 18 – 36 months of age, the foot may appear to roll inward on the arch when the child is standing. This is often normal and does not require treatment if the foot is flexible and the child is walking well. By 6 years of age, the child's foot more closely resembles an adult foot with an arch.



Internal Tibial Torsion (ITT)

When the child is lying flat on the exam table, the foot and the kneecap should both point to the ceiling. ITT is an inward twist of the shinbone which causes the foot to appear to be turned inward when the kneecap is pointing straight ahead. If a small amount of tibial torsion is present in a normal child, the condition usually improves by the time the child is 8 years old.



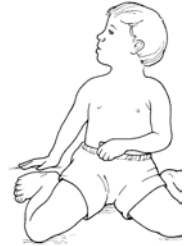

External Tibial Torsion (ETT)

ETT describes an excessive outward rotation of the shinbone. This condition is unusual in normal children but may be seen in adolescents with femoral anteversion. In mild cases, symptoms associated with this condition improve with age.

Femoral Anteversion

Femoral anteversion describes a limitation in outward rotation of the thigh and excessive inward rotation of the thigh. The final amount of twist in the thighbone is set by growth at 9 months of age. Most children do not demonstrate an excessive inward rotation of the thighs until 2 - 4 years of age. Bracing and shoe wear modifications do not affect this condition. Rarely is the twist so severe that the child is unable to walk with the feet pointing straight by 8 years of age.



Femoral Retro torsion / External rotation contracture of the hip capsule

At 4-10 months of age, when the child is lying flat on their back, the feet and legs will appear to completely turn "outward and backwards". This is caused by tightness of the muscles which rotate the hips out. It is most common prior to walking and may benefit from gentle stretching or, in rare cases a nighttime brace.

Age-appropriate Alignment of the legs

At 10-13 months of age when a child first stands, there is an outward bowing of the legs at the knees. This bowleg, or genu varum alignment, is normal for the infant. By 18 months of age, normal growth changes the appearance in 99% of infant legs. The legs appear to come closer together at the knees and further apart at the ankles. This knock-knee or genu valgum appearance may be severe in some children and cause excessive tripping and falling. The genu valgum affects the appearance of the arch of the foot at this time but rarely needs treatment. After 4 years of age, normal growth and development begins to straighten the legs and achieves an adult appearance by eight years of age.

Age appropriate walking pattern

After gaining their balance, a child's initial steps are best described as a flat-footed, waddling, wide-based walking pattern. This initial walking pattern will be continuously modified by the brain and improved with hundreds of hours of muscle activity. Remember though at 2 years of age the child's bowlegs of infancy are going to bend inward severely to become knock-knees. The balance, speed of walking, & likelihood of falling down are affected by this normal growth until at least 4 years of age. Intoeing of one or both feet is common in this age and will improve in a normal child by 8 years of age. An adult-like walking pattern is not seen in children until 8 years of age.

