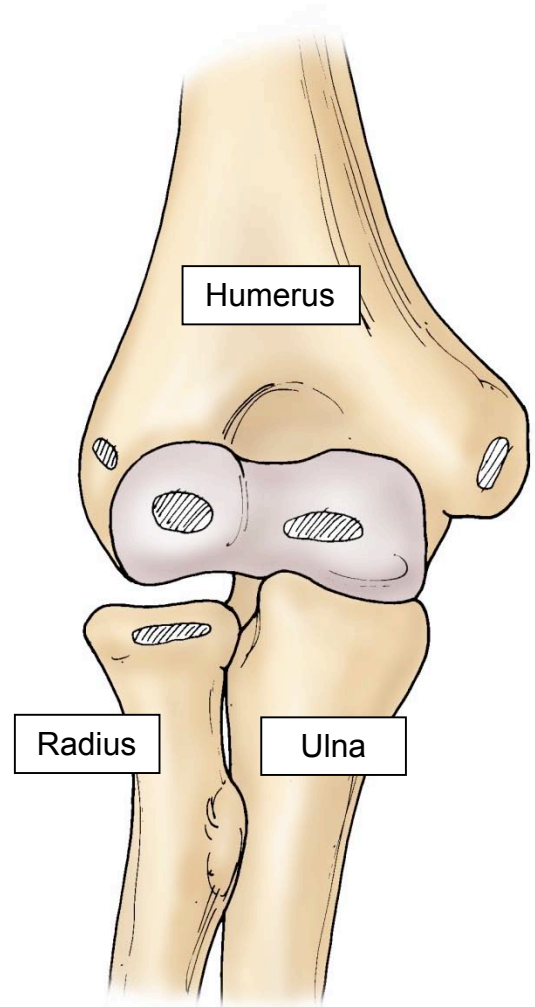


# CONGENITAL RADIOULNAR SYNOSTOSIS

The elbow joint is formed by the end of the humerus, radius and ulna. These three bones together allow for the arm to be flexed up to the mouth and extended fully, as well as contribute to the ability to place the hand in a palm up or palm down appearance. In the first six weeks of life, the embryo creates a projection which is called the limb bud. The limb bud will form these three bones, but certain hormonal or timing factors may not signal the radius and the ulna to form into two separate and discrete bones. If the bones do not form properly, the muscles that rotate the radius and ulna are often absent. This congenital abnormality is usually an isolated event.

Boys will be affected more frequently than girls. 80% of the time both arms will be affected. This disorder can be associated with certain genetic disorders such as acropolysyndactyly (Carpenters syndrome), acrocephalosyndactyly (Apert syndrome), arthrogryposis and Klinefelter syndrome.

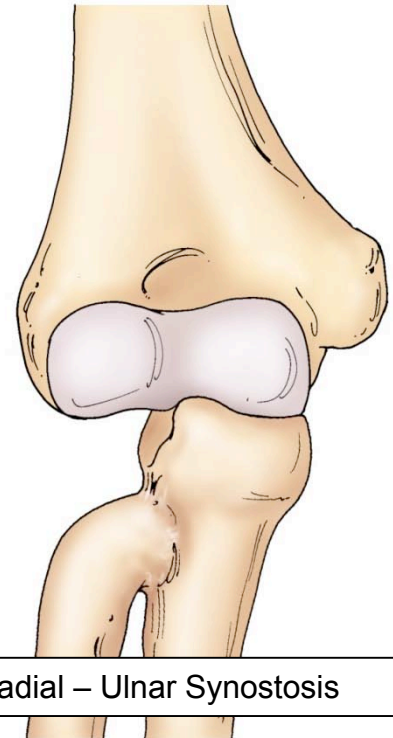
Only a small number of these children are identified at birth. Usually, between eighteen months and three years of age, a parent or teacher notices that activities that involve turning the hand over are difficult for the child. Functional limitations that may prompt the child to be evaluated by a pediatric orthopedist may include: difficulty holding small objects such as pencils, crayons or spoons; difficulty closing and opening shirt buttons, coat buttons or belts; and the inability to rotate a baseball glove in a position to catch a ball.



In addition to the complete lack of motion in the radius and ulna, there is oftentimes a lack of normal motion of the elbow. In assessing individuals the position of the hand relative to the elbow is important. The x-rays will demonstrate that the radius and the ulna are fused together and that the radial head does not have a normal appearance or is completely missing.

## TREATMENT OPTIONS

Treatment options are discussed if there are certain activities of daily living, school tasks or play activities that are particularly difficult to accomplish. There are no surgical techniques that will restore complete palm up and palm down motion in this condition. For a small number of children the hand is stuck in a complete palm down or palm up position. If certain activities of daily living are unable to be performed, then a recommendation to cut the two bones of the arm and rotate the hand in a more functional position. But again, even with this surgical technique the hand will not be able to rotate.



Case reviews still suggest that most children tolerate this birth defect into adulthood without pain or significant functional disability. The family should understand that any operative intervention is unlikely to improve the range of motion but will place the affected hand in an better position for certain activities of daily living.



2660 10<sup>th</sup> Avenue South • POB 1 • Birmingham, AL 35205 • 205-933-8588

All of the content and images on this Brochure are protected by United States and International copyright law and may not copied, scanned, reproduced, published or altered in any way without written permission.

© John T. Killian, MD 2009