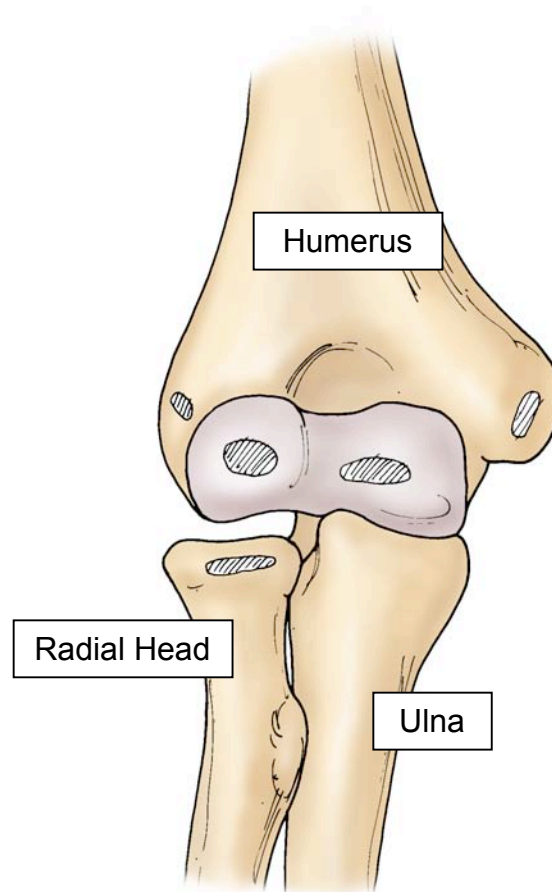


# CONGENITAL DISLOCATION OF THE RADIAL HEAD

The elbow joint is made up of three bones called the humerus, ulna and radius. The portion of the radius that touches or articulates with the humerus is called the radial head. The radial head is curved to match the shape of the lower portion of the humerus, which is called the capitellum. The message that is given to the developing embryo to form an elbow joint occurs sometime in the first six or eight weeks of life. The failure of that message to properly stimulate the formation of the radial head and its alignment with the capitellum occurs fairly rarely but when it does the result is congenital dislocation of the radial head. The diagnosis of an abnormality of the radial head oftentimes is not made until school age. Parents may realize that there is a fullness or a lump on the outside part of the elbow or that the elbow does not flex towards the face as much as the opposite side or compared to other children. The x-rays will demonstrate that the radial head is not aligned with the capitellum in a normal way. The x-rays will show that the radial head is small and rounded and that the capitellum is underdeveloped compared to a normal elbow.



## TREATMENT

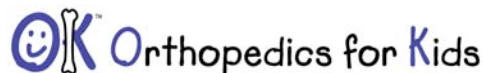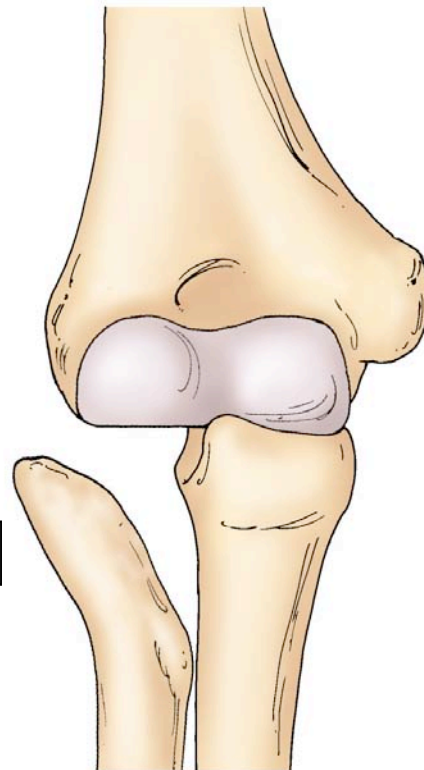
Treatment is necessary only for those children who are having pain or significant limitation of range-of-motion. The inability to fully straighten or bend the elbow is not an indication for surgery. The majority of normal daily activities can be performed without the elbow being perfectly out straight or fully flexed. Occasionally the dislocated radial head may rub the muscles

that move the wrist, causing pain. This bursitis or tendonitis is treated with rest, immobilization and occasionally injection.

When surgery is determined to be needed because of significant, persistent pain or progressive and severe loss of motion, it involves complete removal of the radial head. This allows for slight improvement in range-of-motion. Surgical procedures cannot create a normal joint or produce normal range of motion.

The long term prognosis for children with a congenitally dislocated radial head is that of a painless condition with only a slight loss in physical abilities. Since there is no surgical technique that results in normal growth and development of the radius in the capitellum, surgical procedures are limited to people who experience significant pain as a result of the deformity

The deformed radial head is dislocated



2660 10<sup>th</sup> Avenue South • POB 1 • Birmingham, AL 35205 • 205-933-8588

All of the content and images on this Brochure are protected by United States and International copyright law and may not copied, scanned, reproduced, published or altered in any way without written permission.

© John T. Killian, MD 2009